



Iowa Research Online  
The University of Iowa's Institutional Repository

---

Department of Occupational and Environmental Health Publications

---

6-1-2002

# Translations of the Humerus in Persons with Shoulder Impingement Symptoms

Paula M. Ludewig

Thomas M. Cook  
*University of Iowa*

---

Copyright © JOSPT and the Orthopaedic and Sports Physical Therapy Sections of the American Physical Therapy Association, 2002. Posted by permission.

Journal of Orthopaedic & Sports Physical Therapy, 32:6 (2002) pp.248-259. DOI:10.2519/jospt.2002.32.6.248.

Hosted by [Iowa Research Online](http://Iowa Research Online). For more information please contact: [lib-ir@uiowa.edu](mailto:lib-ir@uiowa.edu).

## Translations of the Humerus in Persons With Shoulder Impingement Symptoms

Paula M. Ludewig, PT, PhD<sup>1</sup>

Thomas M. Cook, PT, PhD<sup>2</sup>

**Study Design:** Two-group mixed-model analysis of covariance and correlation analysis.

**Objectives:** To determine whether differences in humeral translations exist between patients with shoulder impingement symptoms and an asymptomatic comparison group, and if so, to determine if shoulder range-of-motion (ROM) measures are associated with abnormal translations.

**Background:** Abnormal translations of the humeral head are believed to reduce the available subacromial space and to contribute to the development or progression of shoulder impingement symptoms. These abnormal translations have also been theorized to be related to tightness of the posterior capsule and decreased shoulder ROM.

**Methods and Measures:** Three-dimensional humeral translations were tracked in symptomatic construction workers and an asymptomatic comparison group while elevating the arm in the scapular plane under no-load, 2.3-kg, and 4.6-kg hand-load conditions. Between-group comparisons were made across 3 phases of motion (30°–60°, 60°–90°, and 90°–120°) and the association between humeral translations and cross-body adduction and shoulder internal rotation ROM measures were determined by Pearson correlation analysis.

**Results:** Persons with shoulder symptoms demonstrated small but significant changes in anterior-posterior translations of the humerus. These changes for the 90°–120° phase of humeral elevation were moderately negatively associated with available cross-body adduction ROM.

**Conclusions:** The identified kinematic deviations are consistent with possible reductions of the subacromial space. Further study of relationships between posterior capsule tightness, rotator cuff function, and abnormal humeral translations is warranted to better delineate underlying kinematic mechanisms that may contribute to shoulder impingement symptoms and to refine rehabilitation techniques. *J Orthop Sports Phys Ther* 2002;32:248–259.

**Keywords:** *biomechanics, kinematics, shoulder motion abnormalities*

**A**bnormal kinematics of the shoulder have been associated with shoulder pathologies including impingement, instability, and rotator cuff tears.<sup>27,39,40,63,67</sup> It has been estimated that rotator cuff problems, including impingement and associated rotator cuff tendonitis and bursitis, account for nearly one-third of physician visits for shoulder pain complaints.<sup>42</sup> If

not alleviated, impingement can progress to tears of the rotator cuff tendons.<sup>45</sup> Repetitive impingement rather than traumatic injury is believed to be the predominant mechanism of rotator cuff tear development.<sup>45</sup>

Various theories exist regarding the primary mechanism of shoulder impingement. In addition to shoulder kinematic deviations,<sup>17,28</sup> anatomic abnormalities, repetitive eccentric overload, ischemia, and degeneration of the rotator cuff tendons<sup>9,46,53,70</sup> have all been proposed as etiologic factors. Frequent or sustained use of the arm at or above shoulder level during occupational tasks has additionally been identified as a significant risk factor, particularly when holding a load or tool overhead.<sup>6,20,44</sup>

Regardless of the initial etiology, altered rotator cuff function and altered kinematics are believed to perpetuate and exacerbate impingement symptoms.<sup>29,42</sup> Impingement is thought to be due to inadequate space for clearance of the rotator cuff tendons as the arm is elevated, and it has been hypothesized that specific kinematic changes further minimize this space in persons with impingement symptoms.<sup>17,29,34</sup> Using a three-dimensional (3-D) MRI technique, position-dependent subacromial space reductions in the symptomatic shoulders of persons with an impingement diagnosis have been demonstrated.<sup>18</sup> With the arm at 90° of scapular

<sup>1</sup> Assistant professor, Program in Physical Therapy, Department of Physical Medicine and Rehabilitation, The University of Minnesota, Minneapolis, MN.

<sup>2</sup> Professor, Department of Occupational and Environmental Health, Graduate Program in Physical Therapy and Rehabilitation Science, The University of Iowa, Iowa City, IA.

The study protocol was approved by the Human Subjects Committee of The University of Iowa Institutional Review Board.

This investigation was supported in part by a doctoral research award to the primary author from the Foundation for Physical Therapy. The publication was supported in part by the Center to Protect Worker's Rights, Public Health Service, and The University of Iowa under Public Health Service Grant U60/CCU317202. Its contents are solely the responsibility of the authors and do not necessarily represent the official view of the Center to Protect Worker's Rights, the Public Health Service, or The University of Iowa.

Send correspondence to Paula Ludewig, Mayo Mail Code 388, The University of Minnesota, 420 Delaware Street, Minneapolis, MN 55455. E-mail: ludew001@umn.edu

plane abduction in the presence of isometric abductor muscle activity against a load, the subacromial space was reduced by 3 mm as compared to the uninvolved shoulder.<sup>18</sup>

Abnormal superior or anterior translations of the humeral head in the glenoid, and abnormal scapular motions are often proposed as detrimental kinematic abnormalities responsible for the subacromial space reductions in impingement syndrome. Although supporting evidence for abnormal scapular motions in impingement syndrome is increasing,<sup>39,40,63</sup> evidence for abnormal humeral translations is sparse. Poppen and Walker<sup>51</sup> described translations of the humeral head, and instant centers of motion for the scapula and humerus, for 5 intervals of scapular plane abduction in 15 patients with shoulder pain and a comparison group of healthy individuals. Seven patients displayed an abnormal location of the humeral head instant center of rotation (greater than 2 standard deviations from the mean of the healthy subjects), and 6 patients demonstrated increased translation of the humeral head center relative to the glenoid. However, the results of the analysis are complicated by a variety of diagnoses in the patients with shoulder pain, including rotator cuff tears, histories of glenohumeral dislocation, and unspecified shoulder pain.<sup>51</sup>

Using 20° increments of scapular plane abduction, Deutsch et al<sup>13</sup> reported a superior position (by approximately 1 mm) of the humeral head center relative to the glenoid fossa in 15 subjects with impingement syndrome as compared to that of healthy controls. Based on the two-dimensional (2-D) radiographic approach used in both of these studies, descriptions of humeral head translations are limited to static measures in the superior-inferior direction, and are subject to possible projection errors.

Humeral translations during arm elevation in the healthy shoulder are believed to be small, due to a centering effect of rotator cuff forces positioning the humeral head on the glenoid fossa.<sup>19,31</sup> Abnormal translations of the humeral head have been linked to fatigue of the rotator cuff and tightness of the posterior capsule of the shoulder.<sup>8,21</sup> In a cadaver investigation, a 4- to 7-mm increase in mean anterior translation and a 2-mm increase in mean superior translation have been reported during shoulder flexion and cross-body adduction after operatively tightening the posterior capsule with a 2-cm overlap.<sup>21</sup>

Warner et al<sup>62</sup> have identified decreases in humeral internal rotation and cross-body adduction range of motion (ROM) in patients with impingement symptoms. They and others have hypothesized that these ROM deficits may be related to tightness of the posterior glenohumeral joint capsule, and may contribute to impingement symptoms by increasing anterior or superior translations of the humeral head.<sup>48,63</sup>

Clinical treatment of patients with impingement symptoms commonly includes strengthening the rotator cuff and stretching the posterior capsule to restore normal humeral head translations.<sup>14,28,29,48,65</sup>

The purposes of this study were to determine if there were differences in humeral translations between patients with shoulder impingement symptoms and an asymptomatic comparison group, and if so, to determine if shoulder ROM measures are associated with abnormal translations. Specific hypotheses included (1) superior and anterior translations of the humerus relative to the scapula would be increased in the symptomatic group as compared to the asymptomatic group, and (2) humeral internal rotation and cross-body adduction ROM measures would be negatively associated with increased anterior or superior humerus translations.

## METHODS

### Subjects

Subjects eligible for this study included construction workers in either sheet metal or carpentry trades. These trades involve routine occupational exposure to work tasks requiring their upper arms to be at or above shoulder level, and have high rates (40%–50%) of worker shoulder pain.<sup>10</sup> Volunteers with and without shoulder pain were recruited through mailings and announcements at union meetings from a population of approximately 1000 construction workers. All subjects were part of a larger investigation of abnormal kinematics and muscle activity in persons with shoulder impingement symptoms related to occupational exposure to overhead work.<sup>39</sup>

Inclusion and exclusion criteria were assessed for each subject based on a clinical examination performed by the first author. For the symptomatic group, inclusion criteria were as follows: (1) a history of localized anterolateral shoulder pain of greater than 1 week duration; (2) tenderness to palpation of the rotator cuff tendons, a positive impingement test,<sup>24,37,45,60</sup> or a painful arc of movement (60°–120°);<sup>32</sup> and (3) shoulder coronal plane abduction of at least 130° relative to the trunk as measured by goniometer. All symptomatic subjects tested positive for at least 1 impingement test (which included the Hawkins, Neer, and Jobe's tests) and underwent a full screening of cervical and shoulder ROM, resisted motions, and special tests.

Exclusion criteria for both groups were as follows: (1) cervical or shoulder symptoms reproduced by a cervical screening exam;<sup>33</sup> (2) abnormal results with reflex or thoracic outlet tests;<sup>41</sup> (3) symptoms of numbness or tingling in the upper extremity; or (4) a history of the following: onset of symptoms due to traumatic injury, glenohumeral joint dislocation,

acromioclavicular (AC) joint separation, or surgery on the shoulder. Additional exclusion criteria for the asymptomatic group were (1) less than 1 year of employment in an occupation involving overhead work, or (2) a history of pain or trauma in or to the shoulder.

Individual clinical tests generally have either high sensitivity or specificity for the diagnosis of impingement syndrome and not both.<sup>7</sup> No single impingement test has 100% sensitivity or 100% specificity. Therefore, to correctly identify patients with shoulder impingement, a combination or cluster of clinical tests is recommended.<sup>37,60</sup> Ure et al,<sup>60</sup> using a clinical examination with multiple tests, were able to correctly distinguish impingement syndrome from other shoulder pain diagnoses in 86% of cases. The clinical diagnoses in their study were compared to arthroscopically determined diagnoses.<sup>60</sup>

### Instrumentation

The 3-D position and orientation of the subject's thorax, scapula, and humerus were tracked throughout the study using the FASTRAK (Polhemus, Inc., Colchester, VT).<sup>1</sup> Using 3 sensors, the data were sampled at a rate of 40 Hz. By attaching a sensor to a stylus with known tip offsets from the sensor, the system may also be used to manually digitize palpated anatomical coordinates. Within a 76-cm source-to-sensor separation, the reported accuracy of the system is 0.15° root-mean-square (RMS) for orientation and 0.3 to 0.8 mm RMS for position.<sup>49</sup>

### Procedures

Subjects interested in participating in this study were screened by phone interviews for appropriate history and received a written and verbal explanation of the study. Subjects who were included in the study signed university-approved informed consent forms, completed demographic data sheets and the Shoulder Pain and Disability Index (SPADI),<sup>54</sup> and underwent the clinical evaluation. The study protocol was approved by the Human Subjects Committee of the University of Iowa Institutional Review Board. In addition to assessment of inclusion-exclusion criteria, the clinical evaluation included measurement of active humeral internal rotation and cross-body adduction ROM with a standard goniometer.<sup>62</sup> Internal rotation ROM was measured with the subject supine and the arm abducted 90°. Cross-body adduction was measured with the subject supine and an initial arm position of 90° shoulder and elbow flexion. Stabilization of the scapula was provided by the supine position on the mat table. The examiner visually observed for scapular movement off the table. The examiner manually stabilized the subject's arm in the appropriate examining plane (90° abduction for in-

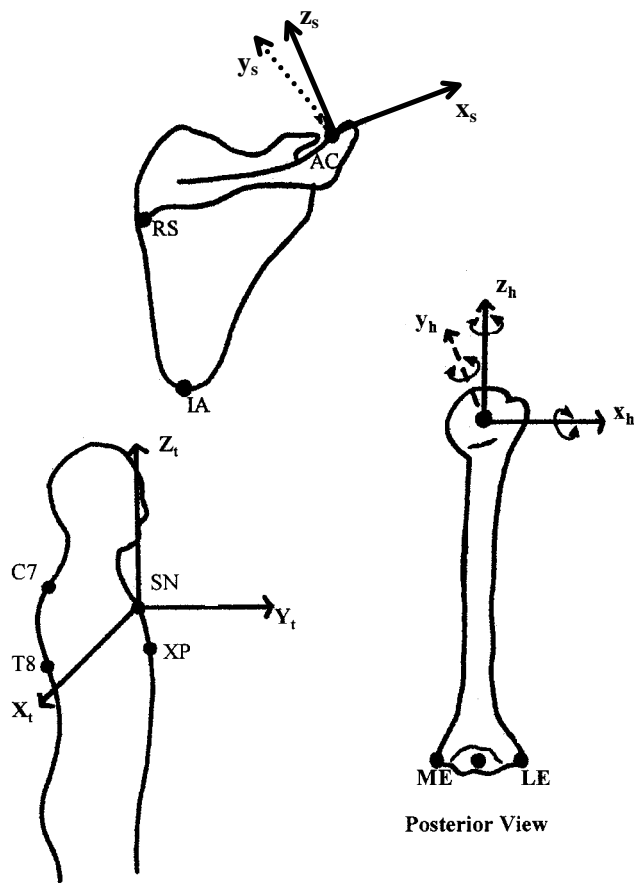
ternal rotation, 90° flexion for cross-body adduction) if needed. The examiner was not blinded to the group assignment of the subjects.

One FASTRAK sensor was attached with adhesive tape to the sternum and a second to the skin overlying the flat superior surface of the scapular acromion process. A third sensor was attached to a thermoplastic cuff secured to the distal humerus with Velcro straps.<sup>39</sup> These surface marker placements have been validated to bone-fixed markers for the humerus and scapula.<sup>30,38</sup>

The subjects stood while bony landmarks on the thorax, scapula, and humerus were palpated and digitized to allow transformation of the sensor data to local anatomically based coordinate systems.<sup>69</sup> These procedures have been previously described and are depicted in Figure 1.<sup>39,43</sup> As the magnitude of translations was anticipated to be related to the size of the humerus, the length of the humerus was determined by digitizing the 3-D coordinates of the estimated center of the humeral head<sup>2</sup> and the lateral epicondyle, and determining the distance between them. The estimated center of the humeral head was determined from data for 20 multiplanar humeral positions at elevation angles of 45° or less relative to the thorax. A least squares algorithm was used to calculate the average pivot point.<sup>2</sup>

Humeral elevation in the scapular plane was matched to a metronome at one complete cycle every 4 seconds. Humeral elevation was guided to remain in the scapular plane by a flat planar surface oriented 40° anterior to the coronal plane and the subject's hand was oriented thumb-up.<sup>36,39</sup> Kinematic data from 5 repetitions of scapular plane humeral elevation through the subjects' full ROM were collected under randomly ordered conditions of no external hand load and hand loads of 2.3 and 4.6 kg. These loads were selected to represent a range of hand loads imposed on a construction worker from power tools or objects lifted overhead. A subsample of 6 subjects returned on the following day for repeat measures of the goniometric and kinematic data.

Raw kinematic data were low-pass filtered at a cut-off frequency of 4.7 Hz (fourth order forward and reverse, zero phase shift digital Butterworth filter).<sup>66,68</sup> Sensor orientation data were transformed to describe relative positions of the anatomical coordinate systems for each segment. When the body is in the anatomical position, the orientation of the x-, y-, and z-axes of each local coordinate system approximate the right, forward, and upward directions, respectively (Figure 1).<sup>39</sup> A series of matrix transformations was used to describe the position and orientation of the humerus at a given time relative to an initial coincident alignment with the thorax to determine humeral elevation angle relative to the thorax (z, y', z' Euler sequence).<sup>3,11</sup> Euler angles de-



**FIGURE 1.** Anatomical coordinate systems for the trunk, scapula, and humerus. RS = root of scapular spine; AC = posterolateral acromioclavicular joint; IA = inferior angle;  $x_s$  = scapular x-axis directed from RS to AC;  $y_s$  = scapular y-axis directed anteriorly perpendicular to the scapular plane;  $z_s$  = scapular z axis directed superiorly; SN = sternal notch; C7 = spinous process of seventh cervical vertebra; T8 = spinous process of 8th thoracic vertebra; XP = xiphoid process;  $X_t$  = trunk x-axis directed laterally;  $Y_t$  = trunk y-axis directed anteriorly;  $Z_t$  = trunk z-axis directed superiorly; ME = medial epicondyle; LE = lateral epicondyle;  $x_h$  = humeral x-axis directed laterally;  $y_h$  = humeral y-axis directed anteriorly;  $z_h$  = humeral z-axis directed superiorly. Adapted from *Physical Therapy*. 2000;80:276–291, with permission of the American Physical Therapy Association.

scribe angular position as a series of 3 rotations about anatomical axes relative to an initial alignment coincident with the thorax coordinate system (Figure 1). The first rotation is about the thorax vertical axis ( $Z_t$ ) and defines the plane of elevation. The second rotation is about the humeral anterior-posterior ( $y_h$ ) axis and defines the humeral elevation angle. The third rotation is about the humeral long axis ( $z_h$ ) and defines internal-external rotation.<sup>3</sup> Humeral elevation angles relative to the thorax determined the independent variable of phases of motion.

Translations of the humerus relative to the scapula were determined for 3 phases (30°–60°, 60°–90°, 90°–120°) of humeral motion relative to the thorax. These phases were of interest as they comprise the arc of motion where impingement is believed to oc-

cur.<sup>15</sup> For each phase, the orientation of the finite helical axis and translation along that axis for humeral motion relative to the scapula were determined from the position and orientation data.<sup>35,58</sup> The helical axis is a single oblique axis about which the humerus is rotating for that specific phase of motion. The z-component of the helical translation vector described the superior-inferior translation of the humerus. Similarly, the y-component of the helical translation vector described the anterior-posterior translation of the humerus. This measure of displacement represents the minimum translation of any points in the humerus, or the translation of the segment relative to the scapula from the initial to the final position within each phase of humeral motion.<sup>4</sup> The points of minimal translation are not fixed points and can change between increments of motion, representing points along the axis of motion for that increment. The location of points along the helical axis relative to the AC joint were determined using methods described by previous authors.<sup>35,58</sup>

The helical axis method of measuring humeral head translations has been assessed for accuracy as compared to humeral bone-fixed measurement.<sup>38</sup> In vivo translation measurements were collected during 3 trials of scapular plane abduction on a subject with a humeral external fixator in place. Measurements made from a sensor attached to the external fixator (bone-fixed) were compared to measurements made from a sensor attached to a surface humeral cuff for 20° increments of humeral motion. When translations were averaged across the 3 trials, the RMS error of the surface technique was 1.5 mm or less.<sup>38</sup> Since bone-fixed measurements were not available from the scapula in this investigation, errors of glenohumeral joint translation measurements may be greater.

Differences between groups for demographic variables, cross-body adduction ROM, and internal rotation ROM were assessed using independent groups *t*-tests. Intraclass correlation coefficients ( $ICC_{3,1}$ )<sup>16,52</sup> and the standard error of measurement (SEM) were used to establish the intrarater trial-to-trial reliability of the kinematic measures for the 3 intermediate trials of each motion. For the subsample of subjects who were retested on a second day, the SEM was used to determine between-day reliability of the goniometric and kinematic measures. The SEM values were determined from a 1-way analysis of variance with subjects as the independent variable. The SEM was determined<sup>16</sup> as the square root of the within-subjects mean square error term.

To address the first hypothesis, this investigation utilized a 3-factor design with fixed factors of group (symptomatic and asymptomatic), load (0.0, 2.3, and 4.6 kg), and phase of movement (30°–60°, 60°–90°, 90°–120°). Measures were made for each group under 3 phases and 3 loads for a total of 9 conditions.



Repeated measures (the 3 intermediate of the 5 trials) occurred under each combination of the phase and load factors. The mean of the 3 intermediate trials was used in data analysis. The group factor was a between-subjects measurement and the load and phase factors were within-subjects measurements. The dependent variables assessed during each phase included anterior-posterior and superior-inferior translations of the humerus relative to the scapula, and superior-inferior (z-coordinate) location of the helical axis in a scapular xz-plane bisecting the AC joint. Because the size of the humerus was believed to potentially influence the magnitude of translation, a covariate of humeral length was considered for translation variables using an analysis of covariance model (ANCOVA).

Hypotheses were tested by fitting univariate ANCOVA models using a significance level of 0.05 for each test. If the analysis identified a significant 3-way interaction effect, contrasts compared group means at each phase and load combination. If significant 2-way interaction effects of group and phase or load were present, contrasts determined group effects at each level of the interacting factor, averaged over the third factor. In the absence of significant interactions, main effects (collapsed across other factors) were assessed. For significant phase effects, Tukey pairwise follow-up analyses were used with adjustment for multiple comparisons.

To address the second hypothesis, Pearson correlations between the ROM and translation measures were determined. Translations for each subject were averaged across load conditions. Correlations were then determined for each of the 3 phases.

## RESULTS

Fifty-two subjects (31 sheet metal workers and 21 carpenters; 26 subjects per group) were able to complete the study. Demographic characteristics and SPADI scores for the subjects are presented in Table 1. Exposure represented the number of years in the trade. There were no significant differences between the groups for any demographic variables. All subjects were male.

Active ROM measurements for shoulder internal rotation and cross-body adduction are presented in Table 2. The 2 study groups were not significantly different for internal rotation ROM ( $df = 51$ ,  $P > 0.15$ ). Group differences ( $7^\circ$ ) for cross-body adduction ROM, however, were significant with  $P < 0.02$ ,  $df = 51$ .

Trial-to-trial ICC and SEM values for the dependent variables are provided in Table 3. Humeral anterior-posterior translations demonstrated ICC values ranging from 0.86 to 0.92 and SEM values from 1.0 to 1.3 mm. Intraclass correlations for humeral superior-inferior translations were lower, ranging from 0.71 to 0.86. However, SEM values reveal low

TABLE 1. Subject demographics (mean  $\pm$  standard deviation) for each subject group.

Demographic	Asymptomatic	Symptomatic
Age (y)	39.9 $\pm$ 13.3	39.7 $\pm$ 12.0
Height (m)	1.80 $\pm$ 0.08	1.81 $\pm$ 0.06
Weight (kg)	85.7 $\pm$ 12.7	90.9 $\pm$ 14.0
Exposure (y)*	18.1 $\pm$ 13.5	16.7 $\pm$ 12.5
Time working overhead (%)*	37.2 $\pm$ 20.6	37.8 $\pm$ 20.4
Number left-hand dominant	4	3
Symptom duration (y)*	—	5.5 $\pm$ 3.2
SPADI <sup>†</sup> pain score	—	20
SPADI <sup>†</sup> disability score	—	28

\* Subject self-report.

<sup>†</sup> Shoulder Pain and Disability Index subscale scores of a possible 100, with higher numbers indicating greater pain or disability. Asymptomatic subjects did not complete the SPADI.

TABLE 2. Average shoulder internal rotation and cross-body adduction range-of-motion measures (mean  $\pm$  standard deviation) for each subject group.

Groups	Internal Rotation ( $^\circ$ )	Cross-Body Adduction ( $^\circ$ )
Asymptomatic	53.2 $\pm$ 10.6	51.2 $\pm$ 9.7
Symptomatic	49.2 $\pm$ 11.0	44.4 $\pm$ 8.9

TABLE 3. Within-day trial-to-trial reliability: intraclass correlation coefficient\* (and standard error of measurement).<sup>†</sup>

Phase of Motion	30°–60°	60°–90°	90°–120°
Humeral anterior-posterior translations	0.89 (1.3)	0.86 (1.0)	0.92 (1.2)
Humeral superior-inferior translations	0.86 (0.6)	0.71 (0.4)	0.84 (0.7)

\* Formula for ICC<sub>3,1</sub>:  $(BMS - EMS) \div [BMS + (k - 1)EMS]$  where BMS = between-subject mean square, EMS = error or within-subject mean square, and k = the number of replicate measures per subject.

<sup>†</sup> Values expressed in mm.

trial-to-trial variability (0.4 to 0.7 mm). The lower ICC for the 60°–90° phase is subsequently a result of minimal between-subject variability for this variable ( $\leq 1$  mm standard deviation). Between-day SEM values for translation variables ranged from 0.3 mm for superior-inferior translation during the 60°–90° phase to 2.3 mm for anterior-posterior translation during the 30°–60° phase. Between-day SEM values for ROM measures were less than  $4^\circ$  for both internal rotation and cross-body adduction.

Figure 2 represents the results of the analysis for humeral anterior-posterior translations. There were no significant interactions with the group factor. There was a significant group main effect ( $df = 1, 50$ ;  $F = 4.07$ ;  $P < 0.05$ ) for this variable. Averaged across loads and phases, the symptomatic group demonstrated approximately 1-mm differences in translations per phase as compared to the asymptomatic group. For the 30°–60° phase, the symptomatic group showed more anterior translation. For the remaining 2 phases, the symptomatic group showed less posterior translation per phase (Figure 2). Averaged

across groups (due to no interactions with group), phase effects ( $df = 2,100$ ;  $F = 144.54$ ,  $P < 0.01$ ) included significantly increased posterior humeral translations for the 60°–90° and 90°–120° phases as compared to their respective previous phases. In the first phase, the humerus translated anteriorly, and small posterior translations occurred for the second and third phases.

Results of the analysis for humeral superior-inferior translations are presented in Figure 3. There were no significant group main effects ( $df = 1,50$ ;  $F = 0.12$ ,  $P > 0.72$ ) or group interaction effects. There was a significant effect of phase ( $df = 2,100$ ;  $F = 21.95$ ,  $P < 0.01$ ). Averaged across groups, the 60°–90° and 90°–120° phases demonstrated significantly less superior translation than the 30°–60° phase. In the first phase, the humerus translated slightly superiorly, and then remained essentially stationary in the superior-inferior direction for the last 2 phases.

Results of the analysis for superior-inferior axis location relative to the AC joint are presented in Figure 4. There were no significant group main effects ( $df = 1,50$ ,  $F = 0.17$ ,  $P > 0.68$ ) or group interaction effects for this variable. Figure 5 provides a lateral

view of axis locations and orientations relative to the AC joint for an individual subject from each group during 1 trial of scapular plane abduction. Helical axis locations varied between subjects, but the 2 study groups were similar with regard to patterns of axis locations.

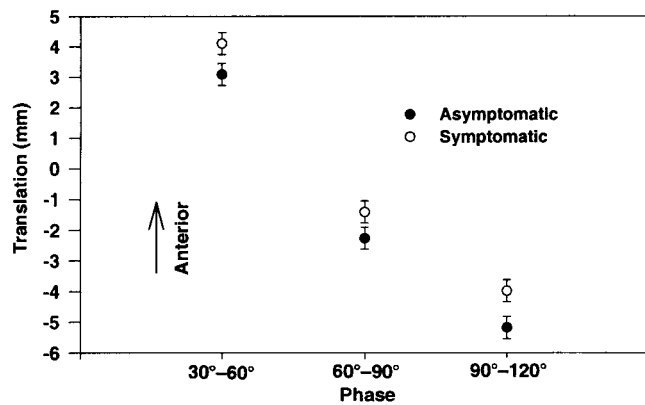


FIGURE 2. Mean values for humeral anterior-posterior translations (error bars indicate  $\pm 1$  standard error of the mean). Groups were significantly different with  $P < 0.05$ .

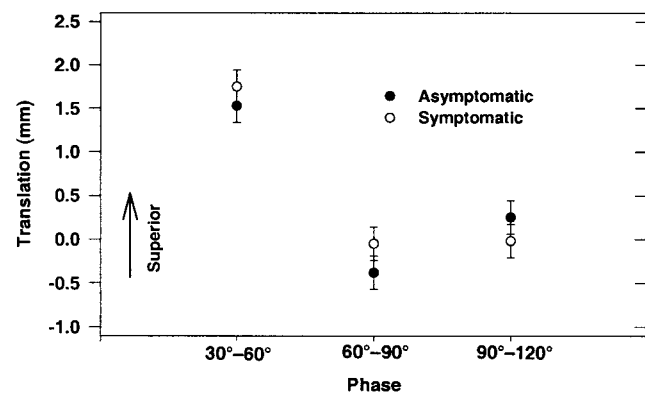


FIGURE 3. Mean values for humeral superior-inferior translations (error bars indicate  $\pm 1$  standard error of the mean). Groups were not significantly different.

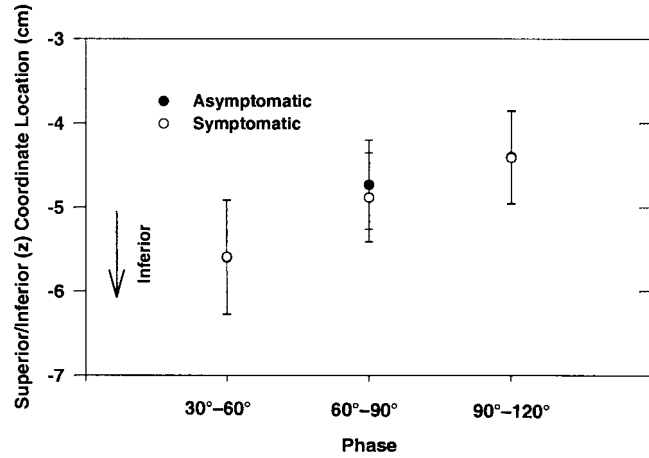


FIGURE 4. Mean values for humeral superior-inferior (z-coordinate) locations of the helical axis in a scapular xz-plane bisecting the AC joint (the error bars indicate  $\pm 1$  standard error of the mean). Groups were not significantly different and mean values were indistinguishable between groups for the 30°–60° and 90°–120° phases.

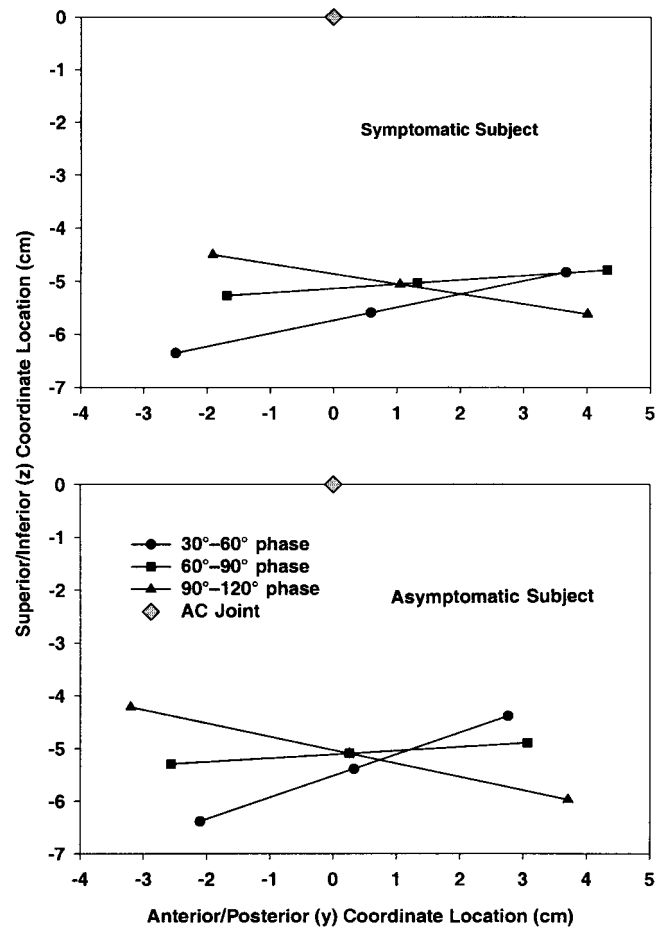


FIGURE 5. Helical axis locations relative to the AC joint from one subject in each group for one trial of scapular plane abduction.

Neither cross-body adduction nor internal rotation ROM measurements were significantly associated with the magnitude of superior-inferior or anterior-posterior translations for the 30°–60° or 60°–90° phases of elevation (Table 4). For the 90°–120° phase, cross-body adduction was significantly associated with the magnitude of anterior-posterior translation ( $r = -.48$ ,  $P < 0.01$ ) (Figure 6). The negative correlation indicates that greater anterior translation (or less posterior translation) is associated with less range of motion. For this same phase, internal rotation was not significantly associated with either translation variable, and cross-body adduction was not significantly associated with superior-inferior translation (Table 4).

## DISCUSSION

The results of this investigation provide partial support for the first hypothesis. Anterior-posterior humeral translations in the symptomatic group were slightly but significantly different as compared to those of the healthy group, for a total difference of 3 mm across the 30°–120° ROM of interest. For the 30°–60° phase, the symptomatic group showed greater anterior translation, and for the remaining phases, a decrease in the mean posterior translation. However, superior-inferior translations were not different between the groups.

Assuming the humeral head started in the same location at the beginning of the 30°–60° phase for both groups, the direction of the anterior-posterior translation changes would result in the humerus being in closer proximity to the anterior undersurface of the acromion, the coracoacromial ligament, and the coracoid process in the symptomatic group. Although small in magnitude, these translation differences may result in greater potential for impingement of the rotator cuff structures as the humerus is elevated. The clinical significance of these small changes must take into consideration the limited size of the subacromial space.<sup>64</sup>

Using simulated muscle forces in cadavers, the subacromial space has been shown to gradually decrease with active elevation of the arm, until reach-

ing approximately 5 mm by 100°–110° of elevation in the scapular plane.<sup>15</sup> Prior to reaching 90° of elevation relative to the scapula, this space must accommodate the articular cartilage, joint capsule and ligaments, rotator cuff tendons, and subacromial bursa, resulting in soft-tissue contact with the undersurface of the acromion during normal elevation of the humerus.<sup>15</sup> Graichen et al<sup>18</sup> reported a 68% reduction in the available subacromial space in individuals with shoulder impingement with an average of a 3-mm smaller space as compared to their asymptomatic shoulder. Zuckerman et al<sup>70</sup> have identified 23% reductions in the available subacromial space in cadaver specimens with full-thickness rotator cuff tears as compared to intact specimens. It seems likely that shoulder impingement may be initiated or exacerbated by even small decreases in the available subacromial space, particularly in combination with inflammation, fibrosis or thickening of the tendons or bursa, or anatomic abnormalities.

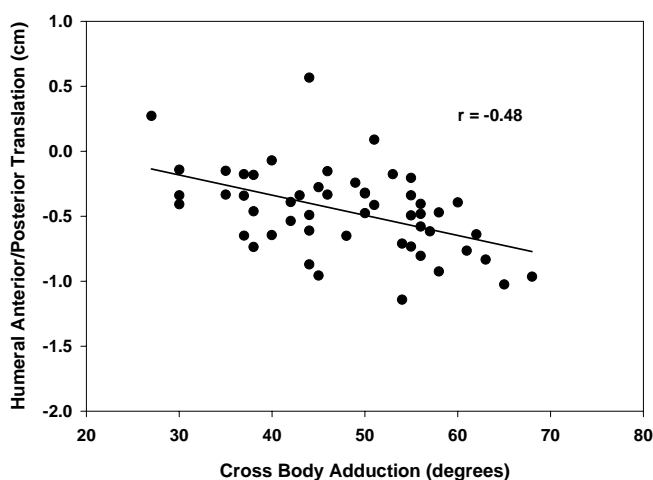
The anterior-posterior humeral head translation data from the present study are difficult to compare to previous reports of humeral head position relative to the scapula in vivo. Howell et al,<sup>25</sup> using static radiographs, reported the humeral head center to be approximately 4 mm posterior when healthy subjects maximally extended and externally rotated in the horizontal plane. With the exception of this position, the humeral head was generally centered relative to the glenoid fossa in the other static horizontal plane test positions.<sup>25</sup> Harryman et al<sup>23</sup> report posterior translations of the estimated humeral head center of 2 and 7 mm in 2 healthy subjects at the end range of passive abduction and external rotation of the arm, respectively. Under the unloaded condition for healthy subjects, mean values from the present study were 2.7 mm anterior, 1.5 mm posterior, and 4.5 mm posterior for each of the 3 phases of interest, respectively. Comparisons between studies of translation data must be considered in light of methodologic differences. No previous reports in the literature describe in vivo helical axis translations of the humerus relative to the scapula during elevation of the arm.

TABLE 4. Correlations between range-of-motion (ROM) and translation measures. (Pearson  $r$  value with  $P$  value in parentheses.)

	Phase of Motion		
	30°–60°	60°–90°	90°–120°
Cross-body adduction (ROM) and anterior-posterior (AP) translation	–0.08 (0.57)	–0.11 (0.45)	–0.48 (< 0.01)*
Cross-body adduction (ROM) and superior-inferior (SI) translation	–0.18 (0.20)	–0.21 (0.14)	–0.04 (0.76)
Internal rotation (ROM) and AP translation	–0.08 (0.58)	0.17 (0.22)	–0.21 (0.13)
Internal rotation (ROM) and SI translation	–0.06 (0.65)	0.06 (0.68)	0.05 (0.70)

\* Statistically significant difference from  $r = 0$ , with  $n = 52$ .





**FIGURE 6.** Scatter plot for association of cross-body adduction range-of-motion and humeral anterior-posterior translation for the 90°–120° phase of motion. The correlation was statistically significant with  $P < 0.01$ ,  $n = 52$ .

Average superior translations in the healthy group during unloaded elevation ranged from 0.1 to 1.6 mm for the 3 phases of interest in this study. These small magnitudes of translations are consistent with previous radiographic values from healthy subjects. Poppen and Walker<sup>51</sup> report averages of 1.1 mm for each 30° change in humeral abduction in the scapular plane beyond the initial 30°. Deutsch et al<sup>13</sup> report 0.7 mm of superior translation between 0° and 120° of humeral elevation.

The role of rotator cuff muscle function during humeral elevation has been described as a means of minimizing the superior translation forces of the deltoid, providing additional abduction torque, improving glenohumeral stability with medially directed compressive forces, and producing external rotation of the humerus.<sup>12,26,50,56,57,61</sup> Decreased force production of the rotator cuff muscles, due to pain-related inhibition or structural damage, has been frequently theorized to allow increased superior translation of the humeral head during elevation, and subsequently contribute to the progression of impingement. The data from the present investigation did not demonstrate the occurrence of this hypothesized process in the group with symptoms of shoulder impingement. Superior translations did not differ between the healthy and symptomatic subject groups. These translations were small in both groups (approximately 2 mm or less) for all phase and load combinations investigated.

The construction workers tested had substantial exposure to overhead work, and reported chronic intermittent symptoms with low levels of impairment and pain (Table 1). As not all symptomatic subjects experienced pain during all portions of the motion testing, theorized pain-related rotator cuff inhibition might not have occurred in some subjects. Results

may be different in subjects with a more acute condition, or subjects with higher levels of pain and impairment. On average, subjects in the present study may not have experienced decreases in rotator cuff function substantial enough to result in altered superior humeral head translations.

Previous studies have identified increases in superior translations of the humeral head in subjects with rotator cuff tears, impingement symptoms, or fatigue of the shoulder muscles.<sup>8,13,51,67</sup> Poppen and Walker,<sup>51</sup> using 2-D radiographs, reported abnormal superior translations or instant-center locations for the humerus in 4 of 7 subjects with rotator cuff tears. In a similar radiographic study, significant increases (approximately 1 mm) in superior migration of the humeral head between 60° to 150° scapular plane abduction in 20 subjects with full thickness rotator cuff tears were described as compared to normal controls.<sup>67</sup> Other investigators also reported significant 1- to 1.5-mm increases in superior translations of the humerus during abduction in the scapular plane in subjects diagnosed with shoulder impingement<sup>13</sup> or shoulder muscle fatigue.<sup>8</sup> These previous data indirectly provide partial support to the contention of rotator cuff forces minimizing superior translation of the humeral head.

It is important to note that the lack of group differences in our study for humeral superior-inferior translations is not likely due to a lack of statistical power. Based on the variability data in this study, the investigation had 80% power to detect superior translation differences between groups as small as 1.5 mm.

The helical axis technique of describing humeral head translations has both advantages and limitations as compared to tracking translations of the anatomical humeral head center. The measured helical translations are not dependent on the base point or point of origin of local coordinate systems. These helical translations represent the minimum translation of any points in the humeral head for a particular phase of motion, and thus are more representative of segment translation.<sup>4</sup> If a fixed humeral center point is tracked, and that point is not on the instantaneous axis of the humerus throughout all intervals of motion, that point will translate even if the segment is undergoing a pure rotational movement. Subsequently, the tracking of a fixed center point can result in overestimated segment translations. Although the helical axis method does not allow the tracking of the anatomical humeral head center throughout the motion, the helical axes determined for 30° increments of humeral elevation in the scapular plane are believed to pass in close proximity to the center of the humeral head for healthy subjects.<sup>31</sup> We verified in our data that the average location of the helical axis was not significantly different

between groups. The axis locations indicate the lack of a fixed axis of rotation, as they do not intersect at a fixed point (Figure 5).

Other limitations of the helical axis technique were also considered. For the theoretical situation where the helical axis is parallel with the anterior-posterior axis, no superior-inferior translations would be identified. We also verified that none of the subjects tested presented with this axis alignment for any phase of the elevation motion. Further, the starting location of the humeral head relative to the glenoid is not identified with the helical axis technique. If different starting locations were present between the groups, the interpretation of the effect of differences in humeral head translations would be confounded. We used the 3-D-estimated humeral head center data for our subjects to test the assumption of a similar humeral starting position. The position of the estimated humeral head center relative to the scapula at the beginning of the 30°–60° phase was not significantly different between the 2 groups (independent groups *t*-test,  $P > 0.05$ ). Further investigation is warranted regarding the merits of the helical axis technique for testing clinical hypotheses regarding humeral head translations in vivo.<sup>5</sup>

The kinematic analysis employed assumes rigid-body mechanics and representation of underlying bone movements with surface sensors. The electromagnetic sensors used are advantageous in requiring only 1 surface placement to acquire 3-D data for a segment. The sensor placements chosen were those with minimal influence of underlying soft-tissue or skin motion. Although minimized, skin slip errors cannot be fully eliminated when using surface sensor measurement techniques.<sup>30,38</sup> Accuracy of the technique used in our investigation is potentially further confounded by use of surface sensors over both the humerus and scapula for descriptions of humeral translations relative to the scapular reference frame.

The results of this study provided limited support for the second hypothesis. Clinically, decreases in humeral internal rotation and cross-body adduction ROM documented in patients with impingement symptoms have been hypothesized to relate to tightness of the posterior glenohumeral joint capsule, and to contribute to impingement symptoms by increasing anterior or superior translations of the humeral head.<sup>42,48,62</sup> Symptomatic subjects in the present study had a significant decrease (approximately 7°) in cross-body adduction ROM compared to the healthy group. For the 90°–120° phase, cross-body adduction ROM was moderately associated with the magnitude of humeral posterior translation. Subjects with lesser values for cross-body adduction ROM tended to have decreased posterior translations during this final phase of interest, which provides some support for the theory of posterior capsule tightness relating to alterations in humeral head translations.

A lack of association between ROM and translations in the earlier phases of motion is not surprising, as capsular tightness has the most potential to impact humeral motion as tension in the capsule increases toward higher arm elevation and end ranges of motion. However, there was no association between internal rotation range of motion and either superior or anterior translations, nor was there an association between cross-body adduction ROM and superior translations.

Support for the posterior capsule tightness theory is provided by the cadaver studies of Harryman et al.<sup>21</sup> These authors compared humeral head translations in cadaver specimens during passive motions before and after operative tightening (2-cm overlap) of the posterior capsule. After surgical tightening, the specimens showed an average increase in anterior translation of 4 and 7 mm during passive flexion and cross-body adduction, respectively. The mean posterior translation during passive extension decreased by 2 mm after operative tightening, and translations were reported to occur earlier in the ROM under the tightened condition.<sup>21</sup>

In the current investigation, the exclusion of persons with a history of traumatic injury to the glenohumeral joint should have minimized the possibility of structural damage contributing to the changes in anterior translations observed. However, it is not possible to determine if decreases in cross-body adduction ROM are actually due to tightness in the posterior capsule, to tightness in other soft tissues of the posterior shoulder, or possibly to anterior soft-tissue restriction in some subjects. Further, it is not known how the 2-cm overlap of the posterior capsule surgically created in the Harryman et al<sup>21</sup> study would relate to the magnitude of posterior capsule tightness that may exist in a clinical population. Cross-body adduction and internal rotation ROM measurements also can be complicated by difficulty stabilizing the scapula. Any of these possible sources of error in the clinical measurements, as well as sources of error in the translation measures, could have reduced the association between ROM and translations.

The lack of blinding to the group status of subjects may have inadvertently biased the ROM measures. However, if present, any such bias was not consistent across ROM measures as no differences between groups were identified for internal rotation ROM. Also, as the examiner was blinded to the humeral translation measurements when collecting the ROM data, any group measurement bias had little potential to impact the associations between ROM and humeral translation measures.

Despite the difficulties with these clinical ROM measurements, we tested our hypotheses using the clinical measurements from which the hypotheses originated, because these measures have been theo-

retically linked to posterior capsule tightness and changes in humeral translations.<sup>62</sup> Recently, a new method of measuring tightness of the posterior shoulder has been proposed that may allow for improved stabilization of the scapula and perhaps a stronger association with abnormal anterior-posterior translations of the humeral head.<sup>59</sup> This investigation focused on links between possible tightness in the posterior capsule and associated abnormal humeral head translations based on the supporting literature. Tightness in the anterior or inferior capsule also has the potential to impact humeral head translations during scapular plane abduction.<sup>22</sup> Inferior capsular restrictions are most often linked with reduced abduction ROM.<sup>55</sup> As greater than 90% of the subjects in the present study had full active ROM for abduction, this area of the capsule was not a focus in our investigation.

The study sample tested is unique in several aspects. The population (sheet metal and carpentry workers) from which the study sample was obtained, is estimated to be 98% to 99% men.<sup>10</sup> No women volunteered as subjects for this investigation. Although no gender differences in humeral translations have yet been reported in the literature, the generalizability of the study results to females is uncertain. Further, results may differ in athletic populations or the elderly. These factors regarding the subject sample must be considered when interpreting the results of the investigation.

Fatigue may also play a role in kinematic alterations associated with impingement symptoms.<sup>8</sup> No investigations of fatigue effects on humeral translations have been completed in symptomatic subjects. Considering the nature of repetitive and/or prolonged overhead work, the influence of fatigue warrants further study in populations with substantial occupational exposure.

## CONCLUSIONS

Persons with symptoms of shoulder impingement demonstrated small but significant changes in anterior-posterior translations of the humerus consistent with possible reductions in the available subacromial space. These changes were moderately negatively associated with available cross-body adduction ROM for the 90°–120° phase of humeral elevation in the scapular plane. Superior-inferior translations did not differ between subjects with and without impingement and were not related to ROM measures. Further study on the relationships between posterior capsule tightness, rotator cuff function, and abnormal humeral translations is warranted in this population to better delineate the underlying kinematic mechanisms that may contribute to shoulder impingement symptoms and to refine rehabilitation techniques.

## ACKNOWLEDGEMENTS

The authors would like to thank Dr. Bing Yu and Professor James Andrews for their assistance with computer programming and mathematical procedures for this investigation. In addition we would like to thank Ms. Anne Johnston, PT, and Ms. Susan Lammers for their assistance with data processing and data collection.

## REFERENCES

1. An KN, Jacobsen MC, Berglund LJ, Chao EY. Application of a magnetic tracking device to kinesiological studies. *J Biomech.* 1988;21:613–620.
2. An KN, Korinek SL, Kilpela T, Edis S. Kinematic and kinetic analysis of push-up exercise. *Biomed Sci Instrum.* 1990;26:53–57.
3. An KN, Browne AO, Korinek S, Tanaka S, Morrey BF. Three-dimensional kinematics of glenohumeral elevation. *J Orthop Res.* 1991;9:143–149.
4. Andrews JG. On the specification of joint configurations and motions. *J Biomech.* 1984;17:155–158.
5. Baeyens JP, Van Roy P, Clarys JP. Intra-articular kinematics of the normal glenohumeral joint in the late preparatory phase of throwing: Kaltenborn's rule revisited. *Ergonomics.* 2000;43:1726–1737.
6. Bjelle A, Hagberg M, Michaelson G. Occupational and individual factors in acute shoulder-neck disorders among industrial workers. *Br J Ind Med.* 1981;38:356–363.
7. Calis M, Akgun K, Birtane M, Karacan I, Calis H, Tuzun F. Diagnostic values of clinical diagnostic tests in subacromial impingement syndrome. *Ann Rheum Dis.* 2000;59:44–47.
8. Chen SK, Simonian PT, Wickiewicz TL, Otis JC, Warren RF. Radiographic evaluation of glenohumeral kinematics: a muscle fatigue model. *J Shoulder Elbow Surg.* 1999;8:49–52.
9. Codman EA. *The Shoulder; Rupture of the Supraspinatus Tendon and Other Lesions in or About the Subacromial Bursa.* Boston, MA: Thomas Todd Co.; 1934.
10. Cook TM, Rosecrance JC, Zimmermann CL. *The University of Iowa Construction Survey; Publication 010-96.* Washington, DC: Center to Protect Worker's Rights; 1996.
11. Craig JJ. *Introduction to Robotics: Mechanics and Control.* New York, NY: Addison-Wesley Company; 1989.
12. De Luca CJ, Forrest WJ. Force analysis of individual muscles acting simultaneously on the shoulder joint during isometric abduction. *J Biomech.* 1973;6:385–393.
13. Deutsch A, Altchek DW, Schwartz E, Otis JC, Warren RF. Radiologic measurement of superior displacement of the humeral head in the impingement syndrome. *J Shoulder Elbow Surg.* 1996;5:186–193.
14. Ellenbecker TS, Derscheid GL. Rehabilitation of overuse injuries of the shoulder. *Clin Sports Med.* 1989;8:583–604.
15. Flatow EL, Soslowky LJ, Ticker JB, et al. Excursion of the rotator cuff under the acromion. Patterns of subacromial contact. *Am J Sports Med.* 1994;22:779–788.

16. Fleiss J. Reliability of measurement. In: Fleiss J, ed. *The Design and Analysis of Clinical Experiments*. New York, NY: John Wiley and Sons; 1986:1–32.
17. Fu FH, Harner CD, Klein AH. Shoulder impingement syndrome: a critical review. *Clin Orthop Rel Res*. 1991;269:162–173.
18. Graichen H, Bonel H, Stammberger T, et al. Three-dimensional analysis of the width of the subacromial space in healthy subjects and patients with impingement syndrome. *Am J Roentgenol*. 1999;172:1081–1086.
19. Graichen H, Stammberger T, Bonel H, Karl-Hans E, Reiser M, Eckstein F. Glenohumeral translation during active and passive elevation of the shoulder—a 3D open-MRI study. *J Biomech*. 2000;33:609–613.
20. Hagberg M, Wegman DH. Prevalence rates and odds ratios of shoulder-neck diseases in different occupational groups. *Br J Ind Med*. 1987;44:602–610.
21. Harryman DT, Sidles JA, Clark JM, McQuade KJ, Gibb TD, Matsen FA. Translation of the humeral head on the glenoid with passive glenohumeral motion. *J Bone Joint Surg Am*. 1990;72:1334–1343.
22. Harryman DT, Sidles JA, Harris SL, Matsen FA. The role of the rotator interval capsule in passive motion and stability of the shoulder. *J Bone Joint Surg Am*. 1992;74:53–66.
23. Harryman DT, Sidles JA, Matsen FA. The humeral head translates on the glenoid with passive motion. In: Post M, Morrey B, Hawkins R, eds. *Surgery of the Shoulder*. St. Louis, MO: Mosby-Year Book; 1990:186–190.
24. Hawkins RJ, Abrams JS. Impingement syndrome in the absence of rotator cuff tear (stages 1 and 2). *Orthop Clin North Am*. 1987;18:373–382.
25. Howell SM, Galinat BJ, Renzi AJ, Marone PJ. Normal and abnormal mechanics of the glenohumeral joint in the horizontal plane. *J Bone Joint Surg Am*. 1988;70:227–232.
26. Inman VT, Saunders JB, Abbott LC. Observations of the function of the shoulder joint. 1944. *Clin Orthop*. 1996;330:3–12.
27. Itoi E, Motzkin NE, Morrey BF, An KN. Scapular inclination and inferior stability of the shoulder. *J Shoulder Elbow Surg*. 1992;1:131–139.
28. Jobe FW, Bradley JP. The diagnosis and nonoperative treatment of shoulder injuries in athletes. *Clin Sports Med*. 1989;8:419–438.
29. Kamkar A, Irgang JJ, Whitney SL. Nonoperative management of secondary shoulder impingement syndrome. *J Orthop Sports Phys Ther*. 1993;17:212–224.
30. Karduna AR, McClure PW, Michener LA, Sennett B. Dynamic measurements of three-dimensional scapular kinematics: A validation study. *J Biomech Eng*. 2001;123:184–190.
31. Kelkar R, Flatow EL, Bigliani LU, et al. A stereophotogrammetric method to determine the kinematics of the glenohumeral joint. *Adv Bioeng*. 1992;22:143–146.
32. Kessel L, Watson M. The painful arc syndrome. Clinical classification as a guide to management. *J Bone Joint Surg Br*. 1977;59:166–172.
33. Kessler RM, Hertling D. *Management of Common Musculoskeletal Disorders: Physical Therapy Principles and Methods*. Philadelphia, PA: Harper & Row; 1983.
34. Kibler WB. Role of the scapula in the overhead throwing motion. *Contemp Orthop*. 1991;22:525–532.
35. Kinzel GL, Hall AS, Jr., Hillberry BM. Measurement of the total motion between two body segments. I. Analytical development. *J Biomech*. 1972;5:93–105.
36. Kondo M, Tazoe S, Yamada M. Changes of the tilting angle of the scapula following elevation of the arm. In: Bateman J, Welsh R, eds. *Surgery of the Shoulder*. Philadelphia, PA: BC Decker, Inc.; 1984:12–16.
37. Leroux JL, Thomas E, Bonnel F, Blotman F. Diagnostic value of clinical tests for shoulder impingement syndrome. *Rev Rheum Engl Ed*. 1995;62:423–428.
38. Ludewig PM. *Alterations in Shoulder Kinematics and Associated Muscle Activity in Persons With Shoulder Impingement Symptoms*. [dissertation]. Iowa City, IA: The University of Iowa; 1998.
39. Ludewig PM, Cook TM. Alterations in shoulder kinematics and associated muscle activity in people with symptoms of shoulder impingement. *Phys Ther*. 2000;80:276–291.
40. Lukasiewicz AC, McClure P, Michener L, Pratt N, Sennett B. Comparison of 3-dimensional scapular position and orientation between subjects with and without shoulder impingement. *J Orthop Sports Phys Ther*. 1999;29:574–83; discussion 584–586.
41. Magee DJ. Cervical spine and shoulder. In: Magee DJ, ed. *Orthopedic Physical Assessment*. Philadelphia, PA: W. B. Saunders Co.; 1987:34–83.
42. Matsen FA, Arntz CT. Subacromial impingement. In: Rockwood C, Matsen F, eds. *The Shoulder*. Philadelphia: W.B. Saunders Co.; 1990:623–646.
43. Meskers CG, Vermeulen HM, de Groot JH, van Der Helm FC, Rozing PM. 3D shoulder position measurements using a six-degree-of-freedom electromagnetic tracking device. *Clin Biomech*. 1998;13:280–292.
44. National Institute for Occupational Safety and Health. Shoulder musculoskeletal disorders: evidence for work-relatedness. In: Bernard BP, ed. *Musculoskeletal Disorders and Workplace Factors: A Critical Review of Epidemiologic Evidence for Work-Related Musculoskeletal Disorders of the Neck, Upper Extremity, and Low Back*. 2nd ed. Publication 97-141. US Department of Health and Human Services, Public Health Service, Centers for Disease Control and Prevention; 1997:1–72.
45. Neer CS. Impingement lesions. *Clin Orthop Rel Res*. 1983;173:70–77.
46. Nirschl RP. Rotator cuff tendinitis: Basic concepts of pathoetiology. *Instr Course Lect*. 1989;38:439–445.
47. Ozaki J. Glenohumeral movements of the involuntary inferior and multidirectional instability. *Clin Orthop*. 1989;238:107–111.
48. Pappas AM, Zawacki RM, McCarthy CF. Rehabilitation of the pitching shoulder. *Am J Sports Med*. 1985;13:223–235.
49. Polhemus Inc. *3SPACE FASTRAK User's Manual, Revision F*. Colchester, VT: 1993.
50. Poppen NK, Walker PS. Forces at the glenohumeral joint in abduction. *Clin Orthop*. 1978;135:165–170.
51. Poppen NK, Walker PS. Normal and abnormal motion of the shoulder. *J Bone Joint Surg Am*. 1976;58:195–201.
52. Portney LG, Watkins MP. *Foundations of Clinical Research: Applications to Practice*. Norwalk, CT: Appleton and Lange; 1993.
53. Rathbun JB, Macnab I. The microvascular pattern of the rotator cuff. *J Bone Joint Surg Br*. 1970;52:540–553.
54. Roach KE, Budiman-Mak E, Songsiridej N, Lertratanakul Y. Development of a shoulder pain and disability index. *Arthritis Care Res*. 1991;4:143–149.
55. Segmuller HE, Taylor DE, Hogan CS, Saies AD, Hayes MG. Arthroscopic treatment of adhesive capsulitis. *J Shoulder Elbow Surg*. 1995;4:403–408.
56. Sharkey NA, Marder RA, Hanson PB. The entire rotator cuff contributes to elevation of the arm. *J Orthop Res*. 1994;12:699–708.

57. Sharkey NA, Marder RA. The rotator cuff opposes superior translation of the humeral head. *Am J Sports Med.* 1995;23:270-275.
58. Spoor CW, Veldpaus FE. Rigid body motion calculated from spatial co-ordinates of markers. *J Biomech.* 1980;13:391-393.
59. Tyler TF, Roy T, Nicholas SJ, Gleim GW. Reliability and validity of a new method of measuring posterior shoulder tightness. *J Orthop Sports Phys Ther.* 1999;29:262-9; discussion 270-274.
60. Ure BM, Tiling R, Kirchner R, Rixen D. The value of clinical shoulder examination in comparison with arthroscopy. A prospective study. *Unfallchirurg.* 1993;96:382-386.
61. van der Helm FC. Analysis of the kinematic and dynamic behavior of the shoulder mechanism. *J Biomech.* 1994;27:527-550.
62. Warner JJ, Micheli LJ, Arslanian LE, Kennedy J, Kennedy R. Patterns of flexibility, laxity, and strength in normal shoulders and shoulders with instability and impingement. *Am J Sports Med.* 1990;18:366-375.
63. Warner JJ, Micheli LJ, Arslanian LE, Kennedy J, Kennedy R. Scapulothoracic motion in normal shoulders and shoulders with glenohumeral instability and impingement syndrome. A study using Moire topographic analysis. *Clin Orthop.* 1992;285:191-199.
64. Warner JJ, Kann S, Maddox LM. The "arthroscopic impingement test". *Arthroscopy.* 1994;10:224-230.
65. Wilk KE, Andrews JR. Rehabilitation following arthroscopic subacromial decompression. *Orthopedics.* 1993;16:349-358.
66. Winter DA. *Biomechanics and Motor Control of Human Movement.* 2nd ed. New York, NY: John Wiley & Sons; 1990:36-41.
67. Yamaguchi K, Sher JS, Andersen WK, et al. Glenohumeral motion in patients with rotator cuff tears: a comparison of asymptomatic and symptomatic shoulders. *J Shoulder Elbow Surg.* 2000;9:6-11.
68. Yu B. *Determination of the Optimum Cutoff Frequency in the Digital Filter Data Smoothing Procedure.* [master's thesis]. Manhattan, KS: Kansas State University; 1988.
69. Zatsiorsky VM. *Kinematics of Human Motion.* Champaign, IL: Human Kinetics; 1998.
70. Zuckerman JD, Kummer FJ, Cuomo F, Simon J, Rosenblum S, Katz N. The influence of coracoacromial arch anatomy on rotator cuff tears. *J Shoulder Elbow Surg.* 1992;1:4-14.