

Persistent vaginal granulation tissue of a large size on the episiotomy scar

Eftekhar Hassan Al-Ojaimi¹

Keywords: Granulation tissue, episiotomy scar, vaginal granulations

Abstract

Although persistent granulation tissue continues to be a well-recognized complication of wound healing, the incidence of episiotomy scar granulation tissue is unknown, and reports are rare. Herein, we present a case of multiple hypertrophied and polypoidal granulation tissue of a large size at the site of episiotomy scar treated with surgical excision and the recovery was uneventful with excellent results.

¹*Department of Obstetrics and Gynecology , Al Zahra Hospital Dubai, Dubai, United Arab Emirates*

Introduction

Hypertrophic granulation tissue, often referred to as overgranulation or proud flesh,¹ is a well-documented complication of wound healing. It is characterized by exuberant growth of granulation tissue during the proliferative stage of wound healing, which prevents

maturation and epithelialization.² It readily bleeds due to increased vascularization and a lack of protective epithelial barrier.^{1,3} It is usually not painful as it contains little nerve tissue, however, if left untreated, innervation can occur which will increase sensation and cause pain.³ The incidence of vaginal granulations is difficult to assess. Although well known to practicing obstetricians, there seems to be very little detailed description of this condition in the literature.⁴ Atia and Tidbury described four patients with localized polypoid lesions of granulation tissue on the episiotomy scar, three patients had a single lesion while the remaining one had three lesions, and the sizes of the lesions were ≤ 1 cm.⁴ Herein, we report a 34-year-old woman with multiple hypertrophied and polypoidal granulation tissues about three to six cm

Please cite this paper as: Al-Ojaimi EH. Persistent vaginal granulation tissue of a large size on the episiotomy scar. POG in Press. 2020 September; Article 2 [7 p.]. Available from: http://ir.uiowa.edu/pog_in_press/. Free full text article.

Corresponding author: Dr. Eftekhar Hassan Al-Ojaimi, P.O. Box. 37320, Dubai, United Arab Emirates. Tel. 0097156 6608555. Fax. 009714 3481255. e-mail: eojaimi@gmail.com

Financial Disclosure: *The author reports no conflict of interest.*

Copyright: © 2020 Al-Ojaimi. This is an open-access article distributed under the terms of the Creative Commons Attribution License, which permits unrestricted use, distribution, and reproduction in any medium, provided the original author and source are credited.

long at the site of episiotomy scar. To the best of our knowledge, this is the largest and most numerous vaginal granulation tissue on the episiotomy scar reported in the literature.

Case Report

A 34-year-old primipara, presented to our clinic complaining of excessive yellowish, non-foul-smelling vaginal discharge with no associated vulvar itching, on and off since her delivery. It was profuse to such an extent that she was showering three times a day and using disposable under-pads to protect her clothes from secretions. The discharge was sometimes mixed with blood especially after sexual intercourse but there was no history of dyspareunia. The patient had previously seen several physicians for the same complaint but denied improvement of symptoms despite taking different types of antibiotics. She had had a difficult vaginal delivery with forceps and episiotomy five months prior to her presentation. There was no other significant past medical or surgical illness.

On vaginal examination, excessive

granulation tissue was seen filling the whole vagina, which looked hypertrophied and polypoidal about three to six cm long. The uterus was normal, and both adnexa were clear. The vulva and perineum appeared normal. On speculum examination, old blood was seen in the vagina and the cervix appeared healthy. The exact origin of the granulation tissue could not be determined in the clinic even by gently rotating the speculum due to the large size and numerous amounts. Gram stained smears from the urethra, vagina and cervix, vaginal swab cultures for *Neisseria gonorrhoea* and *Chlamydia* together with a PAP smear were taken. The reports of all were negative. In view of the unusual large size and the excessive amount of granulation tissue, examination under anesthesia with surgical excision of the granulation tissue was planned.

The procedure was done under general anesthesia. Intraoperative findings revealed excessive granulation tissue in the posterior vaginal wall along the line of the episiotomy scar up to the posterior fourchette. It looked hypertrophied and polypoidal (Figure 1 A and B).

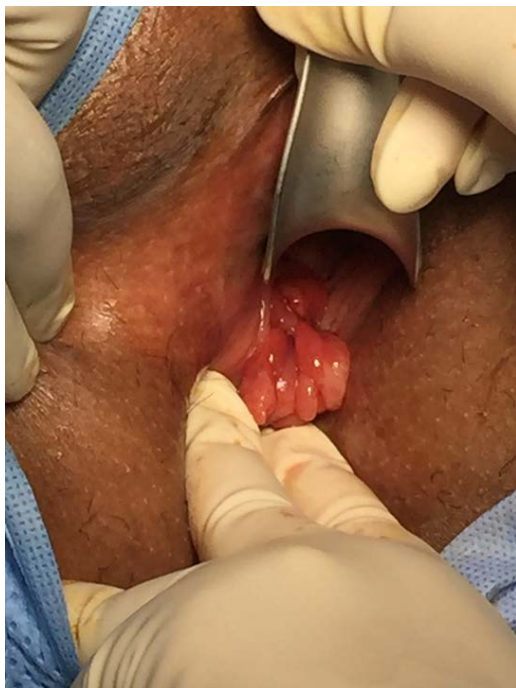

Figure 1(A)

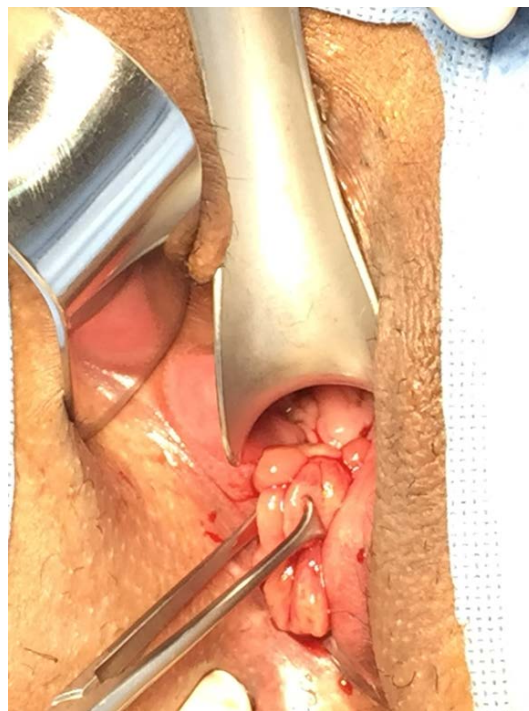


Figure 1(B)

Figure 1. Excessive hypertrophied and polypoidal granulation tissues (A) in the posterior vaginal wall (B) grasped with *Allis* tissue forceps.

There was no granulation tissue or polyps in other parts of the vagina or perineum (Figure 2). The granulation tissue was excised completely (Figure 3) and sent for histopathology. Postoperative recovery was uneventful. The histopathological report revealed multiple fragments of tissue, the largest measured 6 cm in dimension, with inflamed granulation tissue reaction. No granuloma, dysplasia or evidence of malignancy was seen. At the sixth week

postoperative follow up visit the patient stated that she felt quite well. The vaginal discharge had disappeared within a week of surgery and she felt that one shower a day instead of three was enough. On examination the healing was perfect with normal appearance of the vagina and no recurrence of the granulation tissue. Three months later, the patient remains asymptomatic with no signs or symptoms of recurrence.

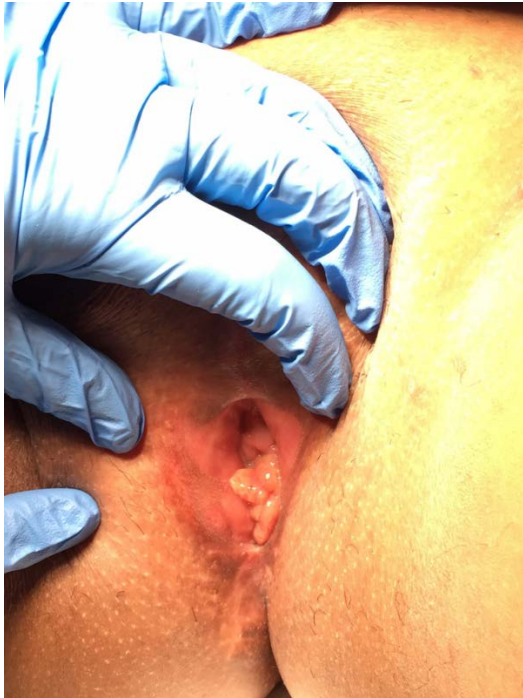


Figure 2. No granulation tissue was seen in the perineum, the lesions were localised inside the vagina

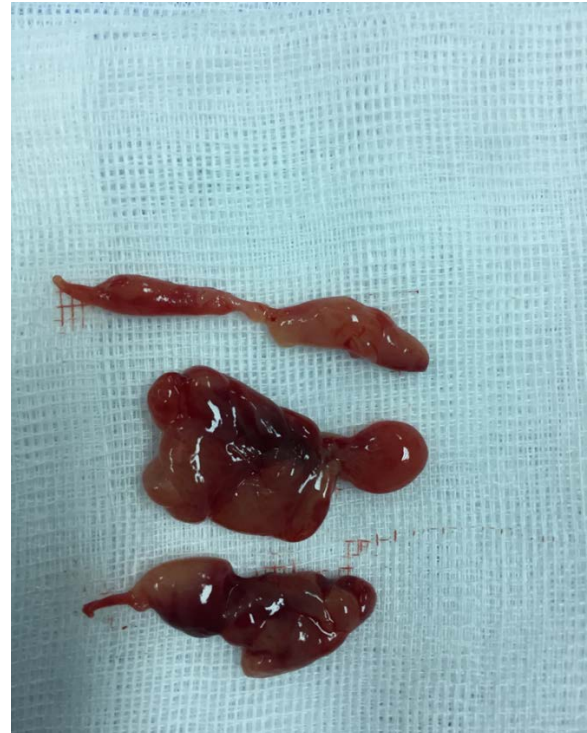


Figure 3. Some of the excised granulation tissues

Discussion

Although the formation of some granulation tissue is a normal component of the wound-healing cascade, this tissue may become pathologically excessive and persist in the vagina and perineum. The etiology behind the development of hypergranulation tissue is not well understood.⁵ Predisposing factors that have been suggested include chronic inflammation, external friction, infection, and foreign-body irritation.^{1,6} Vaginal granulation tissue is more frequently reported after hysterectomy. Saropala and Ingsirorat analyzed 352 patients who underwent total abdominal

hysterectomy, vault granulation tissue was found in 119 patients, giving the incidence of 34 %.⁷ In another study of 471 patients who underwent hysterectomy with vaginal vault closure, a comparison between 220 women who had abdominal versus 261 women who had vaginal route closure of the vault was done, the prevalence of granulation tissue was found to be similar in the two groups.⁸ The incidence of the granulation tissue on the episiotomy scar is unknown and reports are rare. It should be noted that in many of the large surveys evaluating episiotomy, the long-term assessment, which is usually three months, was often

accomplished by a postal questionnaire as it seems that a late clinical examination was impractical. However, in one prospective study conducted by Beischer, the protocol did include clinical assessment at three months. He studied 56 patients who had persistent dyspareunia due to a badly repaired episiotomy incision and he found granulomata in 24 of them, giving an incidence of 42.9%.⁹ In research by Ketcham et al., episiotomy scars were examined at sixth weeks postpartum. A scar with granulation tissue was found in 16 out of 42 women sutured with chromic catgut and in three out of 37 women sutured with polyglycolic acid.¹⁰ However, we suspect that this condition may be much more common in clinical practice than is stated by the rarity of published reports. To find out the true incidence of episiotomy scar granulation tissue, a prospective study of a postnatal cohort, including clinical examination, is required.

Vaginal discharge is a common gynecological symptom with a wide range of causes. For proper management of such a problem, as described in our patient, other causes of this symptom should be excluded by full clinical assessment and laboratory investigations. Clinical presentations of vaginal granulation tissue include dyspareunia, genital discomfort, vaginal discharge, which may be bloody, or postcoital bleeding. Alternatively, it may be completely

asymptomatic.⁷ In our patient the only symptom was excessive yellowish vaginal discharge sometimes mixed with blood. The profuse quantity of discharge in this case could be related to the large size and excessive amount of the granulation tissue.

There are different therapeutic options for vaginal granulation tissue. Cauterization with silver nitrate is the most commonly used treatment. Although the procedure itself is easy and quick to perform, it often needs to be repeated on several occasions, and it is not appropriate for multiple large lesions due to its ability to cause tissue necrosis.¹¹ Steinberg et al. discussed a case where carbon dioxide laser had been used for treatment of persistent vaginal granulation tissue.¹² Saropala and Ingsirorat studied the spontaneous regression rate of vault granulation tissue in 100 patients who underwent total abdominal hysterectomy at the 10th, 14th and 20th week after the operation.⁷ They found complete regression of the lesions in 52 patients, of these 56% regressed at the 10th week, 23% at the 14th week and the remaining 21% at the 20th week.⁷ When they further analyzed the relationship between the size of the granulation tissue and spontaneous regression rate, they found that complete regression rate was 72% of the lesions which were ≤ 5 mm and 33% of those which were >5 mm.⁷ Thus, conservative treatment would be reasonable if the lesions were small ≤ 5 mm and asymptomatic. Large granulation tissue >10 mm is very rare; it was found in 8 out of 105 patients, giving the incidence of 7.6

%.⁷ In our woman, the size of the granulation tissue was much bigger which ranged from three to six cm. Therefore, surgical excision of the granulation tissue was chosen as the modality of treatment in this case due to the large size and numerous amounts. In addition to cure, this procedure has an advantage of providing a biopsy sample to confirm diagnosis and exclude malignancy.

Conclusion

In conclusion, vaginal granulation tissue at the site of the episiotomy scar may be associated with unpleasant symptoms, mainly vaginal discharge with or without dyspareunia. These granulations should be looked for in symptomatic postnatal patients who may present several months after delivery. This condition often necessitates treatment especially if the lesions are large and excessive as described in this case. Episiotomy scar granulations may be more common than the paucity of published reports suggests. Further research regarding its incidence, causation and prevention could prove beneficial and improve postpartum recovery for many women.

Declarations

Conflicting interests: The author declared no potential conflicts of interest with respect to the research, authorship, and/or publication of this article.

Funding: The author received no financial support for the research, authorship, and/or publication of this article.

Ethical approval: All procedures performed in the study involving human participants were in accordance with the ethical standards of the institutional and /or national research committee and with the 1964 Helsinki declaration and its later amendments or comparable ethical standards.

Informed consent to participate: Informed consent was obtained from the patient included in the study.

Informed consent to publish: Informed consent was obtained from the patient to publish her case.

References

1. Harris A, Rolstad BS. Hypergranulation tissue: a nontraumatic method of management. *Ostomy Wound Manage.* 1994 Jun;40(5):20-2, 24, 26-30. PMID: 7546080.
2. Young T. Common problems in wound care: overgranulation. *Br J Nurs.* 1995 Feb 9-22;4(3):169-70. <https://doi.org/10.12968/bjon.1995.4.3.169> PMID: 7703668.
3. McGrath A. Overcoming the challenge of overgranulation. *Wounds UK.* 2011 Mar; 7(1): 42-49.
4. Atia WA, Tidbury PJ. Persistent episiotomy granulation polyps; a polysymptomatic clinical entity. *Acta Obstet Gynecol Scand.* 1995 May;74(5):361-6. <https://doi.org/10.3109/00016349509024429> PMID: 7778429.

5. Madden K, Paghdal KV, Cohen G. Potassium titanyl phosphate 532-nm laser for treatment of a chronic nonhealing exophytic wound with hypergranulation tissue. *Dermatol Surg.* 2011 May;37(5):716-9. <https://doi.org/10.1111/j.1524-4725.2011.01976.x> Epub 2011 Apr 1. PMID: 21457396.
6. Hanlon M, Heximer B. Excess granulation tissue around a gastrostomy tube exit site with peritubular skin irritation. *J Wound Ostomy Continence Nurs.* 1994 Mar;21(2):76-7. <https://doi.org/10.1097/00152192-199403000-00005> PMID: 7804407.
7. Saropala N, Ingsirorat C. Conservative treatment of vaginal vault granulation tissue following total abdominal hysterectomy. *Int J Gynaecol Obstet.* 1998 Jul;62(1):55-8. [https://doi.org/10.1016/S0020-7292\(98\)00054-X](https://doi.org/10.1016/S0020-7292(98)00054-X). PMID: 9722126.
8. Hwang JH, Lee JK, Lee NW, Lee KW. Vaginal cuff closure: a comparison between the vaginal route and laparoscopic suture in patients undergoing total laparoscopic hysterectomy. *Gynecol Obstet Invest.* 2011;71(3):163-9. <https://doi.org/10.1159/000316052> Epub 2010 Dec 14. PMID: 21160140.
9. Beischer NA. The anatomical and functional results of mediolateral episiotomy. *Med J Aust.* 1967 Jul 29;2(5):189-95. <https://doi.org/10.5694/j.1326-5377.1967.tb97711.x> PMID: 6057891.
10. Ketcham KR, Pastorek JG 2nd, Letellier RL. Episiotomy repair: chronic versus polyglycolic acid suture. *South Med J.* 1994 Apr;87(4):514-7. <https://doi.org/10.1097/00007611-199404000-00018> PMID: 8153782.
11. Hampton S. Understanding overgranulation in tissue viability practice. *Br J Community Nurs.* 2007 Sep;12(9):S24-30. <https://doi.org/10.12968/bjcn.2007.12.Sup4.43000> PMID: 18026011.
12. Steinberg BJ, Mapp T, Mama S, Echols KT. Surgical treatment of persistent vaginal granulation tissue using CO(2) laser vaporization under colposcopic and laparoscopic guidance. *JSLS.* 2012 Jul-Sep;16(3):488-91. <https://doi.org/10.4293/108680812X13462882736619> PMID: 23318081; PMCID: PMC3535803.