

Tubal splenosis: unusual location of the spleen

Sema Baki,¹ Alper Basbug,² Burcu Yılmaz Hanege,¹ Nazan Özsan³

Keywords: Splenosis, pelvic mass, tubal splenosis, pelvic pain

Abstract

Introduction: Splenosis is defined as the autotransplantation of splenic tissue to abnormal locations after splenic injury. Heterotopic spleen can be found within the abdominal and pelvic cavities. We report a tubal splenosis case in a 48 year old woman who underwent splenectomy following a blunt trauma 41 years prior to presentation.

Case report: A 48 years old gravida 3, para 3, was admitted to our gynecology clinic for pelvic pain, menstrual irregularities and abnormal bleeding. The patient had a six months history of sonographically detected 40 x 20 mm pelvic mass. She also had a blunt trauma and splenectomy history from 41 years ago. Total abdominal hysterectomy with bilateral salpingo-oophorectomy was performed. Intraoperative exploration revealed a 40 mm sized suspicious mass immediately adjacent to the right fallopian tube. The histopathologic examination of the specimen reported normal splenic tissue with polymorphous small lymphocytes, granulocytes, and frequent hemosiderin laden macrophages.

Discussion: Posttraumatic pelvic splenosis is a rare condition. Splenosis should be kept in mind as a differential diagnosis especially for patients with a history of posttraumatic splenectomy who are scheduled for pelvic mass surgery. Although most of the patients are diagnosed postoperatively, if preoperative diagnosis could be made, there is no medical indication for this

normally functioning tissue to be resected.

¹*Obstetrics and Gynecology Department, Giresun Obstetrics-Gynecology and Pediatrics Training and Research Hospital, Giresun, Turkey*

²*Department of Obstetrics and Gynecology, The University of Düzce, Düzce, Turkey*

³*Department of Pathology, Ege University, İzmir, Turkey*

Introduction

The spleen can have an extensive variety of anomalies including its shape, location, number, and size. Most of these anomalies are congenital but there are also acquired types. Splenosis is an acquired anomaly of the spleen which happens in the case of splenic injury or splenectomy. Splenosis is reported to occur in 16–67% of patients after splenic surgery or traumatic rupture of the spleen. Heterotopic autotransplantation and implantation of the splenic tissue can be found anyplace in the peritoneal cavity but pelvic splenosis is rare. Splenosis is mostly asymptomatic and found incidentally on ultrasound(US),

Please cite this paper as: Baki S, Basbug A, Hanege BY, Özsan N. Tubal splenosis: unusual location of the spleen. Proc Obstet Gynecol. 2017;7(2): Article 10 [4 p.]. Available from: <http://ir.uiowa.edu/pog/> Free full text article.

Corresponding author: Alper Basbug, Department of Obstetrics and Gynecology, The University of Düzce, Düzce, Turkey, drajper23@gmail.com

Financial Disclosure: The authors report no conflict of interest.

Copyright: © 2017 Baki et al. This is an open-access article distributed under the terms of the Creative Commons Attribution License, which permits unrestricted use, distribution, and reproduction in any medium, provided the original author and source are credited.

computed tomography (CT), and magnetic resonance imaging (MRI) examinations. However, it is often misdiagnosed as malignant tumors, with the patients undergoing unnecessary operations.¹⁻³

Case report

A 48 years old gravida 3, para 3, was admitted to our gynecology clinic for pelvic pain, menstrual irregularities and abnormal bleeding. The patient had a six month history of a sonographically detected 40 x 20 mm pelvic mass. Doppler imaging was performed but showed no abnormal vascularization and arterial resistance was normal. She also had a blunt trauma and splenectomy history from 41 years ago.

She had no background or family history of related diseases. After six months of follow-up there was no decrease in the size of the pelvic mass. After obtaining the patient's consent total abdominal hysterectomy with bilateral salpingo-oophorectomy was performed. Intraoperative exploration revealed a 40 mm sized suspicious mass immediately adjacent to the right fallopian tube. The histopathologic examination of the specimen reported normal splenic tissue with polymorphous small lymphocytes, granulocytes, and frequent hemosiderin laden macrophages. No pelvic mass was detected in the postoperative first and sixth months of follow-up and patient's pain disappeared after the surgery.

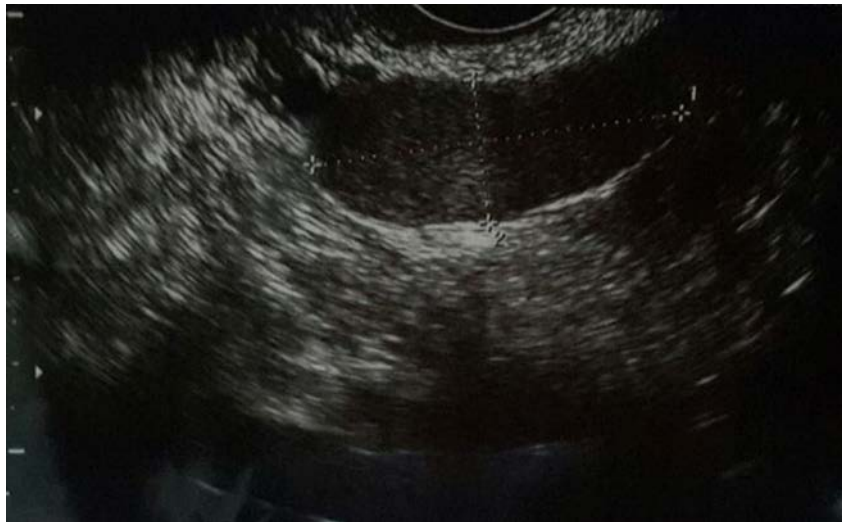

Figure 1 Ultrasound image demonstrating pelvic mass.

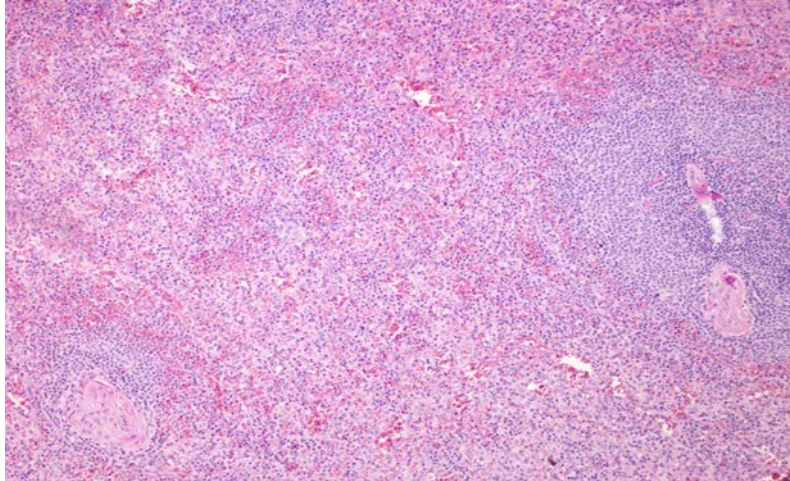


Figure 2 Histopathological image of pelvic mass.

Discussion

Splenic tissue can be found in two different forms in the body. The first one is the accessory spleen. The accessory spleen usually roots from the left side of the dorsal mesogastrium during embryological development and is nourished from a branch of the splenic artery. On the other hand splenosis is acquired and it can be located peritoneally or extra peritoneally. It is nourished from nearby tissues or vascular structures.⁴ Splenosis cases usually are asymptomatic and won't get diagnosed. Masses that are diagnosed are generally of patients operated on for a malignancy suspicion.⁵ In this case report, we present a pelvic tubal splenosis case which was diagnosed coincidentally after a long asymptomatic period. Though posttraumatic intraperitoneal splenosis cases are reported, thus derived gynecological problems are not commonly seen and data at hand is restricted concerning this issue.⁶ In this case we attributed the pelvic pain to splenosis.

Diagnosis of splenosis is generally confirmed after imaging studies and surgical explorations for other conditions. Standard computed tomography and magnetic resonance imaging are sensitive in detecting and describing the location of implants with scintigraphy being the gold standard.⁷ In our patient, it was diagnosed after exploration for an adnexal mass. In addition to a proper history and physical exam, a blood smear showing the absence of Howell-Jolly, Pappenheimer, or Heinz bodies is indicative of the presence of functional splenic tissues.⁸

The interval of time between the initial trauma and the diagnosis varies from 3 to 45 years with an average interval of 21 years.⁹ In our case the interval time was a long period of time for 41 years.

Asymptomatic splenosis cases can be managed conservatively. Patients undergoing operations are usually misdiagnosed cases. Surgery is totally curative but if splenectomy patients operated for hematological indications show no remission postoperatively a

case of possible splenosis should be kept in mind.¹⁰

Conclusion

Posttraumatic pelvic splenosis is a rare condition. Splenosis should be kept in mind as a differential diagnosis especially for patients with a history of posttraumatic splenectomy who are scheduled for pelvic mass surgery. Although most of the patients are diagnosed postoperatively, if diagnosed preoperatively, there is no medical indication for this normally functioning tissue to be resected.

References

1. Liu Y, Ji B, Wang G, Wang Y. Abdominal multiple splenosis mimicking liver and colon tumors: a case report and review of the literature. *Int J Med Sci.* 2012;9(2):174-7. <https://doi.org/10.7150/ijms.3983> Epub 2012 Jan 26. Review. PubMed PMID: 22359484; PubMed Central PMCID: PMC3283864.
2. Menth M, Herrmann K, Haug A, Raziorrouh B, Zachoval R, Jung CM, Otto C. Intra-hepatic splenosis as an unexpected cause of a focal liver lesion in a patient with hepatitis C and liver cirrhosis: a case report. *Cases J.* 2009 Aug 19;2:8335. <https://doi.org/10.4076/1757-1626-2-8335> PubMed PMID: 19830070; PubMed Central PMCID: PMC2740154.
3. Yildiz AE, Ariyurek MO, Karcaaltincaba M. Splenic anomalies of shape, size, and location: pictorial essay. *ScientificWorldJournal.* 2013 Apr 21;2013:321810. <https://doi.org/10.1155/2013/321810> PubMed PMID: 23710135; PubMed Central PMCID: PMC3654276.
4. Halpert B, Gyorkey F. Lesions observed in accessory spleens of 311 patients. *Am J Clin Pathol.* 1959 Aug;32(2):165-8. <https://doi.org/10.1093/ajcp/32.2.165> PubMed PMID: 13670140.
5. Bizekis CS, Pua B, Glassman LR. Thoracic splenosis: mimicry of a neurogenic tumor. *J Thorac Cardiovasc Surg.* 2003 May;125(5):1155-6. <https://doi.org/10.1067/mtc.2003.312> PubMed PMID: 12771890.
6. Zitzer P, Pansky M, Maymon R, Langer R, Bukovsky I, Golan A. Pelvic splenosis mimicking endometriosis, causing low abdominal mass and pain. *Hum Reprod.* 1998 Jun;13(6):1683-5. <https://doi.org/10.1093/humrep/13.6.1683> PubMed PMID: 9688412.
7. Short NJ, Hayes TG, Bhargava P. Intra-abdominal splenosis mimicking metastatic cancer. *Am J Med Sci.* 2011 Mar;341(3):246-9. <https://doi.org/10.1097/MAJ.0b013e318202893f> PubMed PMID: 21446083.
8. Lake ST, Johnson PT, Kawamoto S, Hruban RH, Fishman EK. CT of splenosis: patterns and pitfalls. *AJR Am J Roentgenol.* 2012 Dec;199(6):W686-93. <https://doi.org/10.2214/AJR.11.7896> PubMed PMID: 23169741.
9. Yammine JN, Yatim A, Barbari A. Radionuclide imaging in thoracic splenosis and a review of the literature. *Clin Nucl Med.* 2003 Feb;28(2):121-3. <https://doi.org/10.1097/01.RLU.0000048681.29894.BA> PubMed PMID: 12544129.
10. Toktaş O, Yavuz A, İliklerden Ü, Yılmaz D, Bayram İ. Intrahepatic splenosis after splenectomy performed for idiopathic thrombocytopenic purpura. *Ulus Cerrahi Derg.* 2015 Jul 10;31(4):247-9. <https://doi.org/10.5152/UCD.2015.2746> PubMed PMID: 26668536; PubMed Central PMCID: PMC4674051.